

Ch. 47 Somatic Sensations: Tactile and Position Senses (Reading Homework Ch. 47)

- Somatic senses: three types
 - (1) Mechanoreceptive somatic senses: tactile and position sensations
 - (2) Thermoreceptive senses: heat and cold
 - (3) Pain sense: damage in tissue
- Other classifications
 - (1) Exteroreceptive sensations: from the surface of the body
 - (2) Proprioceptive sensations: physical state of body, position sensations, tendon and muscle sensations
 - (3) Visceral sensations: sensations from internal organs
 - (4) Deep sensations: sensations from deep tissue.
- ◆ **Detection and transmission of tactile sensations**
 - Three principle differences in touch, pressure, and vibration
 - (1) Touch sensations from stimulation of tactile receptors in the skin or tissue
 - (2) Pressure sensation from deformation of deep tissue
 - (3) Vibration sensation from rapidly repetitive sensory signals
 - Tactile receptors: special characteristics
 - (1) Free nerve endings: Everywhere in the skin. Detect touch and pressure
 - (2) Meissner's corpuscle: Elongated encapsulated nerve endings. Excites a large myelinated sensory nerve fiber (A-type). In the non-hairy parts of the skin. Abundant in the fingertips, lips, and other areas where touch sensation is highly developed.
 - (3) Merkel's discs: Expanded tip tactile receptors. Transmit an initially strong but partially adapting signal and then a continuing weaker signal that adapts only slowly. Responsible for giving steady-state signals

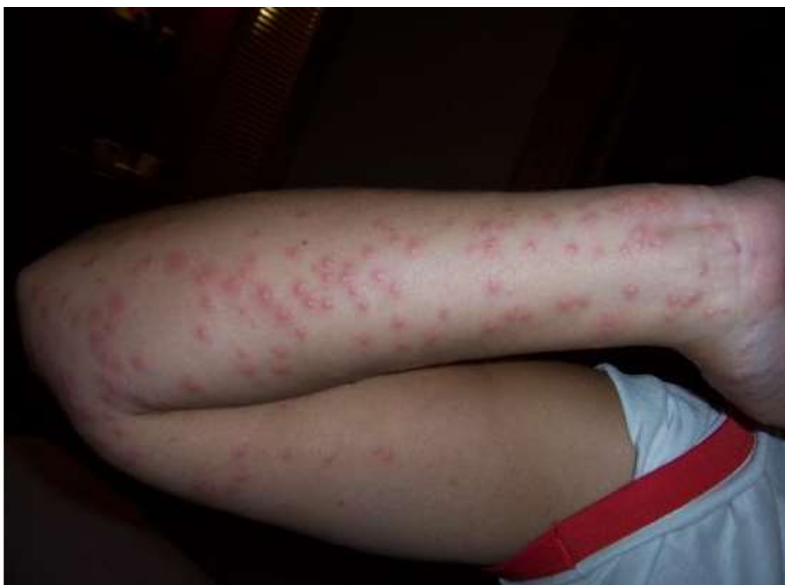- (4) Hair end-organ: Slight movement of any hair on the body stimulates the nerve fiber. Detects movement of objects on the surface of the body
- (5) Ruffini's end-organs: In the deeper layers of the skin. Adapts very slowly. Signaling continuous states of deformation of the skin and deeper tissues
- (6) Pacinian corpuscle: Lie both immediately beneath the skin and deep in the facial tissues of the body. Stimulated only by rapid movement of the tissues.
- Transmission of tactile sensations in peripheral nerve fibers: transmit signals in type $A\beta$ nerve fibers with transmission velocities ranging from 30 to 70m/sec
 - Detection of vibration
 - All different tactile receptors are involved in detection of vibration
 - Different receptors detect different frequencies of vibration
 - Pacinian corpuscles: 30 to 800 cycles per sec
 - Meissner's corpuscles: 2 to 80 cycles per sec
 - Tickling and itch
 - Very sensitive, rapidly adapting mechanoreceptive free nerve endings
 - Elicit only the tickle and itch sensations
 - In the superficial layers of the skin
 - Very small type C, unmyelinated fibers similar to those that transmit the aching, slow type of pain

Quiz




Itch

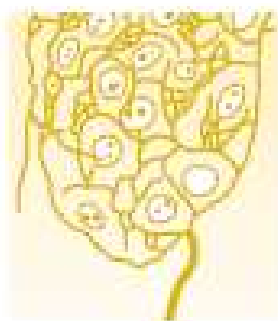vs.



Tickle




Free nerve endings



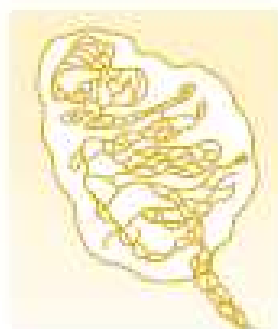
Expanded tip receptor



Tactile hair



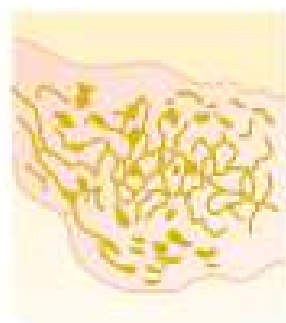
Pacinian corpuscle



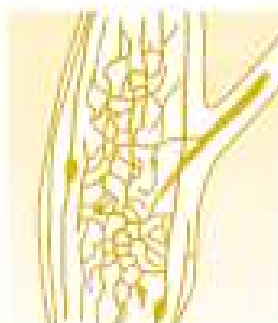
Meissner's corpuscle



Krause's corpuscle



Ruffini's end-organ



Golgi tendon apparatus

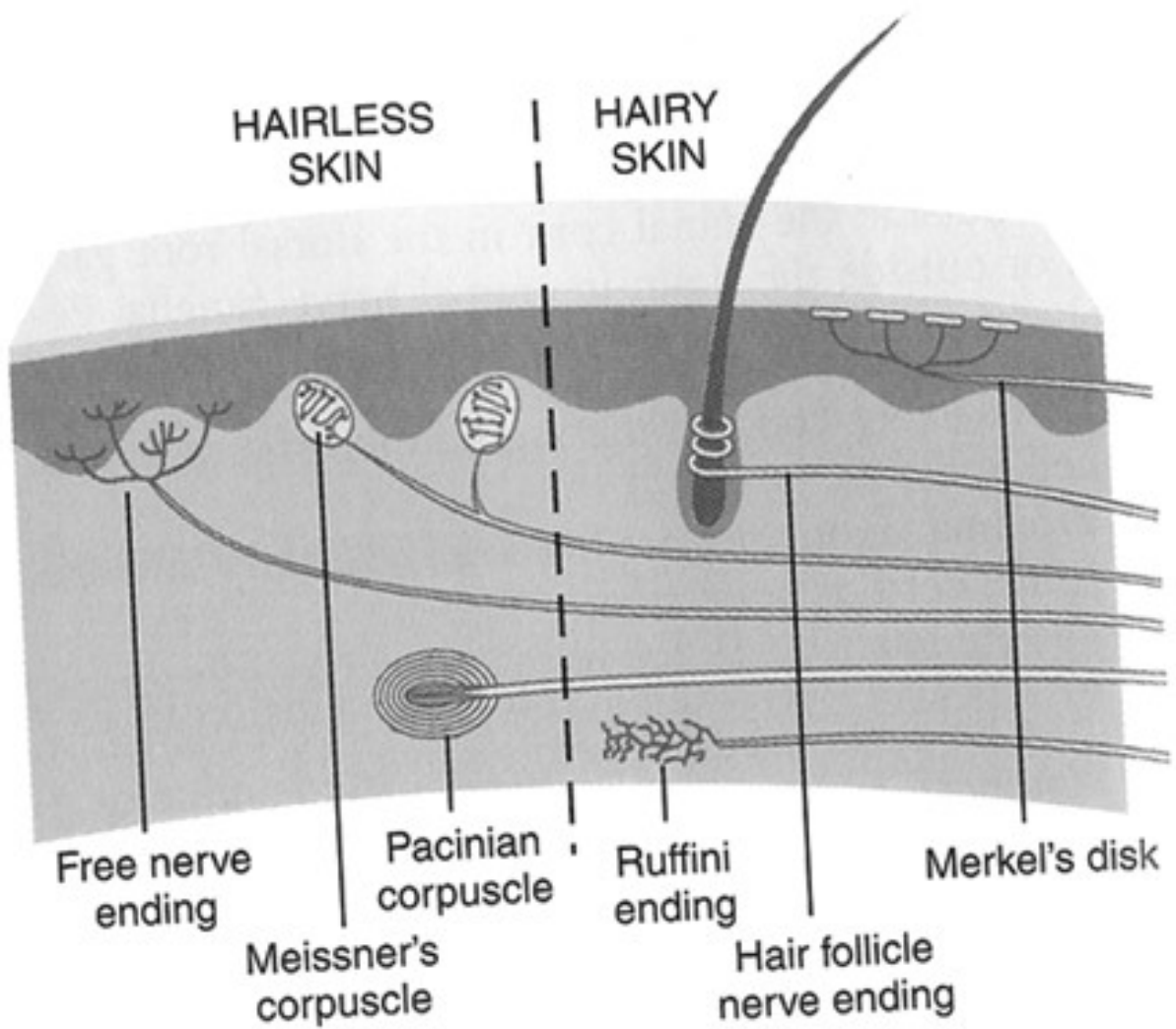


Muscle spindle

Figure 46-1

Several types of somatic sensory nerve endings.

Hairy vs. Hairless



◆ Sensory pathways for transmitting somatic signals into the central nervous system

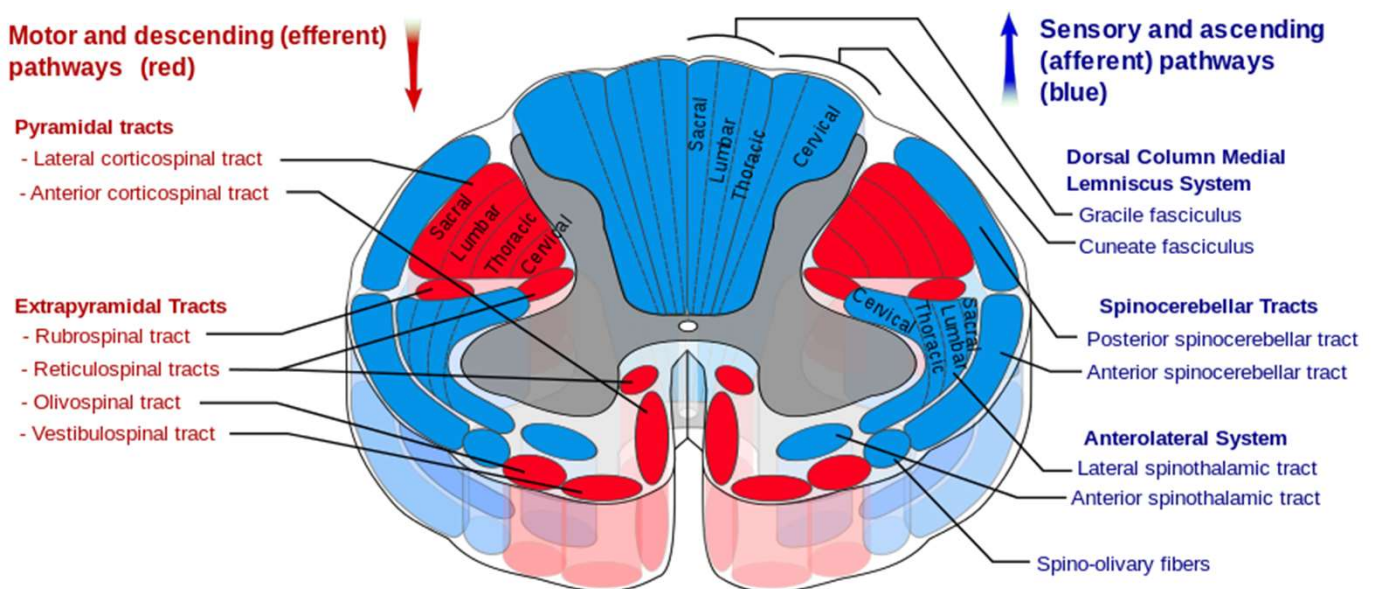
Dorsal = “back” in Latin

Lemniscus = “ribbon” or “band” in Greek

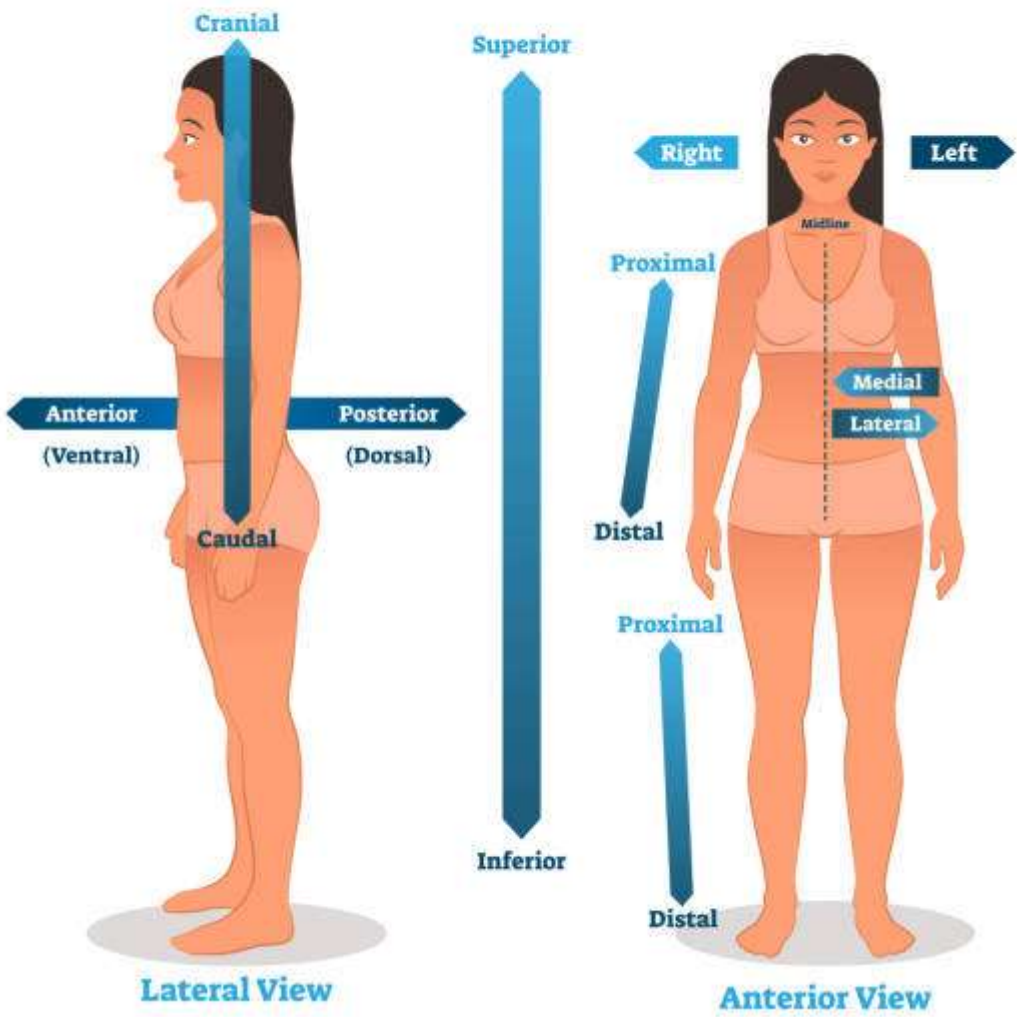
Two sensory pathways

(1) Dorsal column-medial lemniscal system

- Carries signals in the dorsal columns of the spinal cord
- Signals synapse and cross to the opposite side in the **medulla**
- Through the **brain stem** to the **thalamus** by way of the **medial lemniscus**
- Composed of large, myelinated nerve fibers that transmits signals to the brain with velocities of 30 to 110m/sec
- High degree of spatial orientation of the nerve fibers
- Sensory information that must be transmitted rapidly and with temporal and spatial fidelity
- Limited to the discrete types of mechanoreceptive sensations



ANATOMICAL POSITION



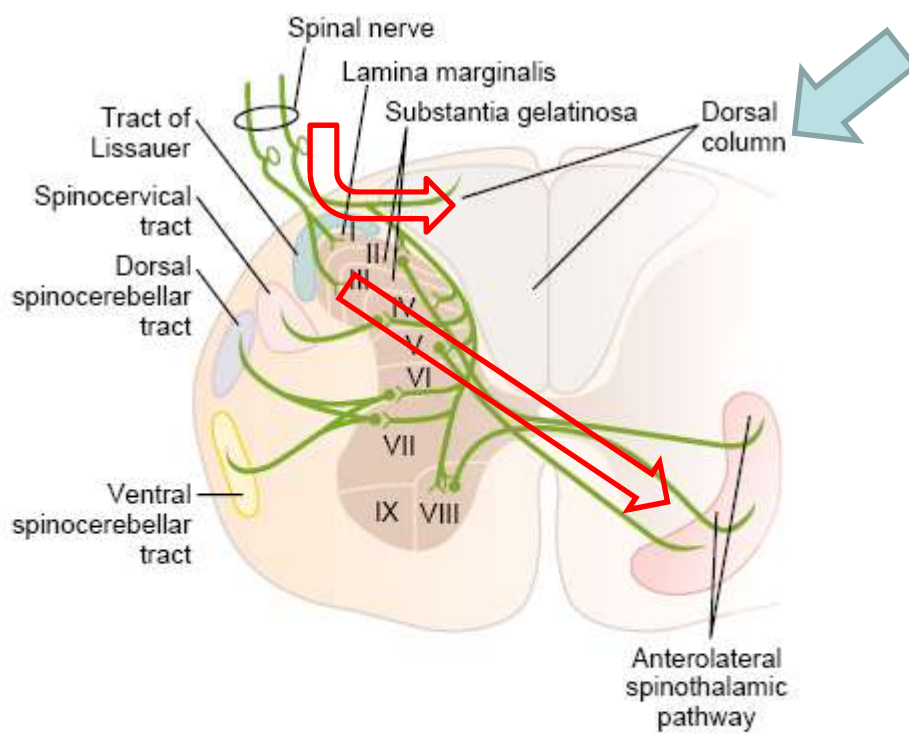
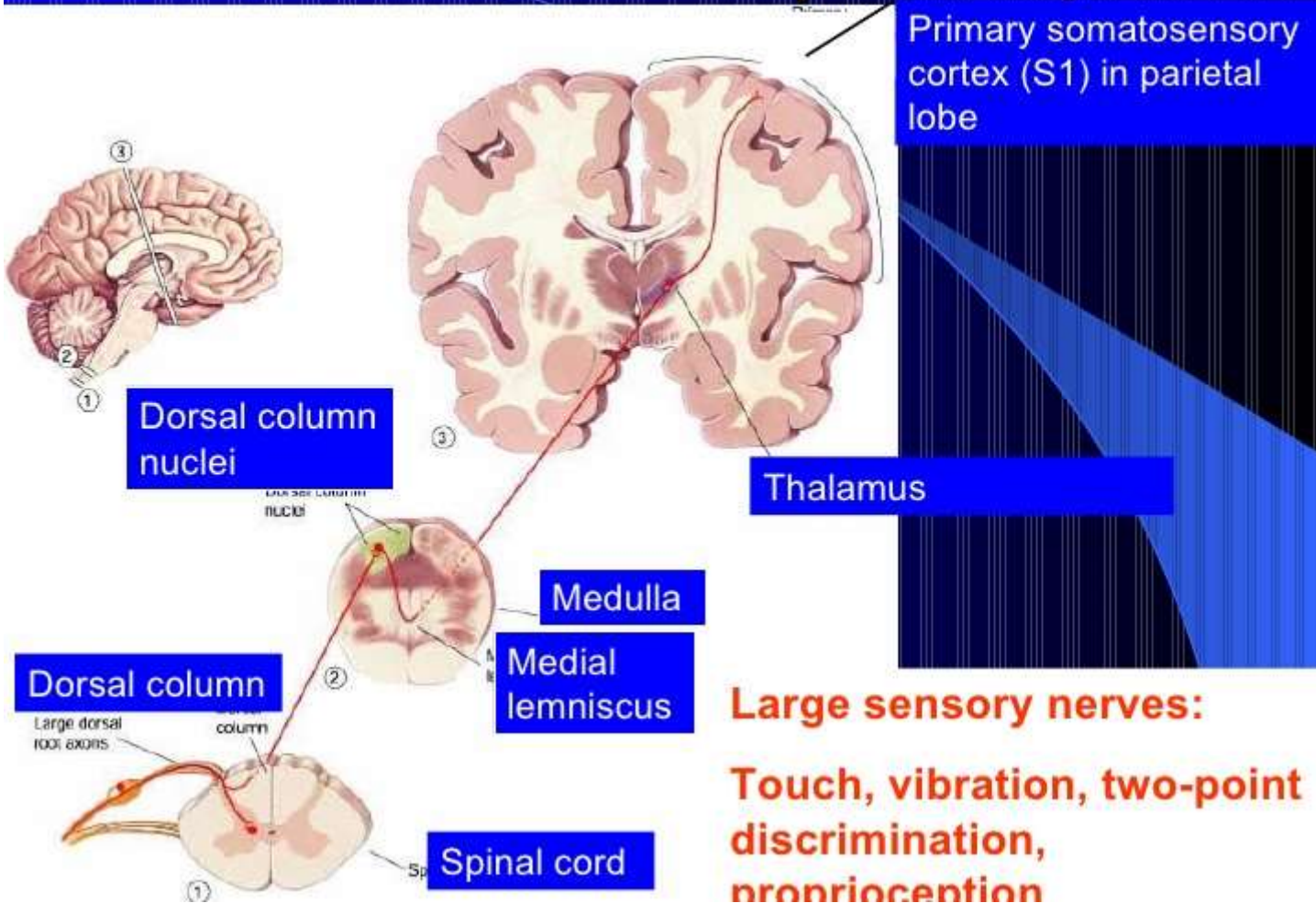


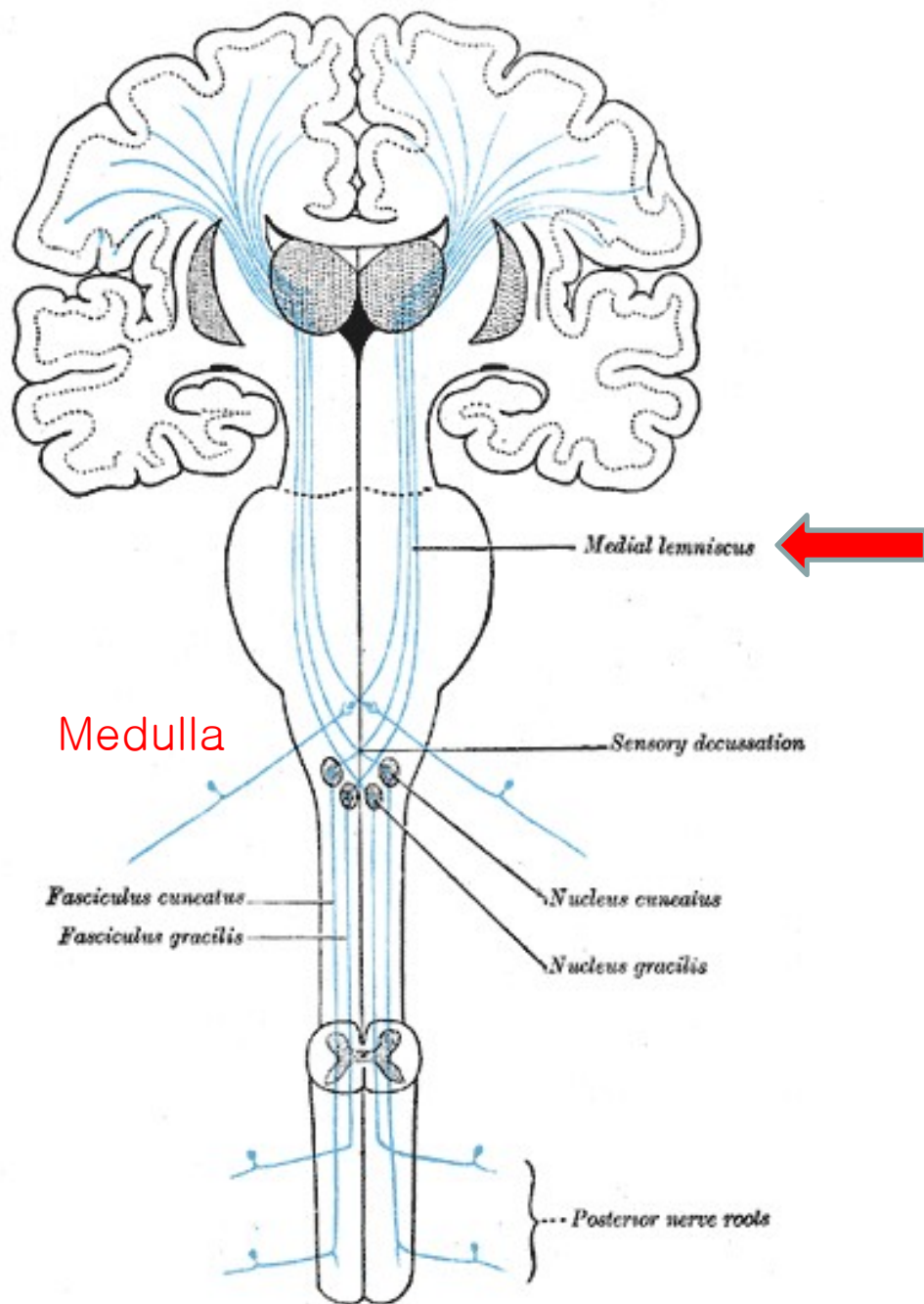
Figure 47-2

Cross section of the spinal cord, showing the anatomy of the cord gray matter and of ascending sensory tracts in the white columns of the spinal cord.

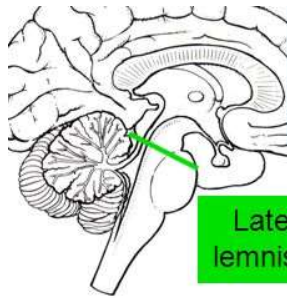
Dorsal column pathway



Dorsal column-medial lemniscal system



Rostral Pons



Superior cerebellar peduncle

Cerebral aqueduct

Lateral lemniscus

Medial longitudinal fasciculus

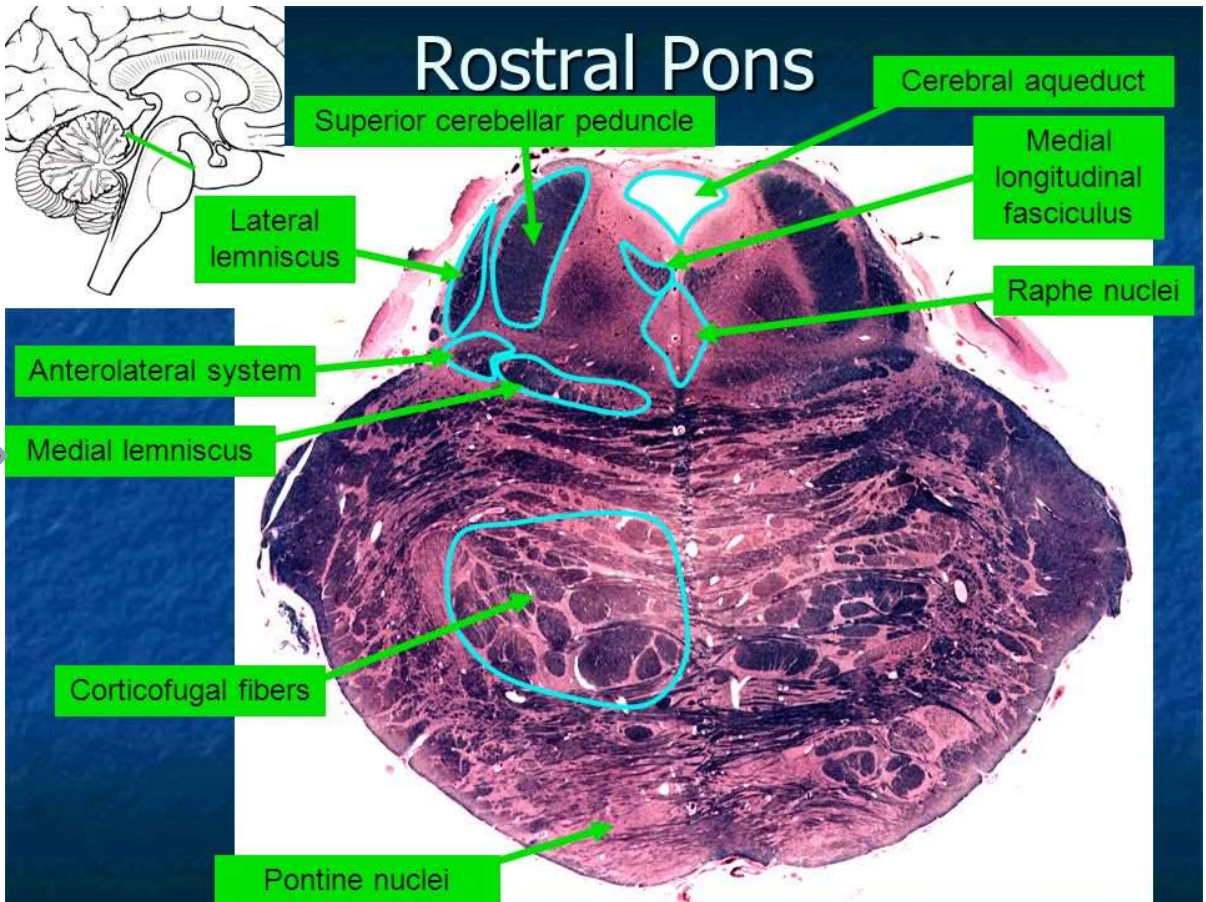
Raphe nuclei

Anterolateral system

Medial lemniscus

Corticofugal fibers

Pontine nuclei



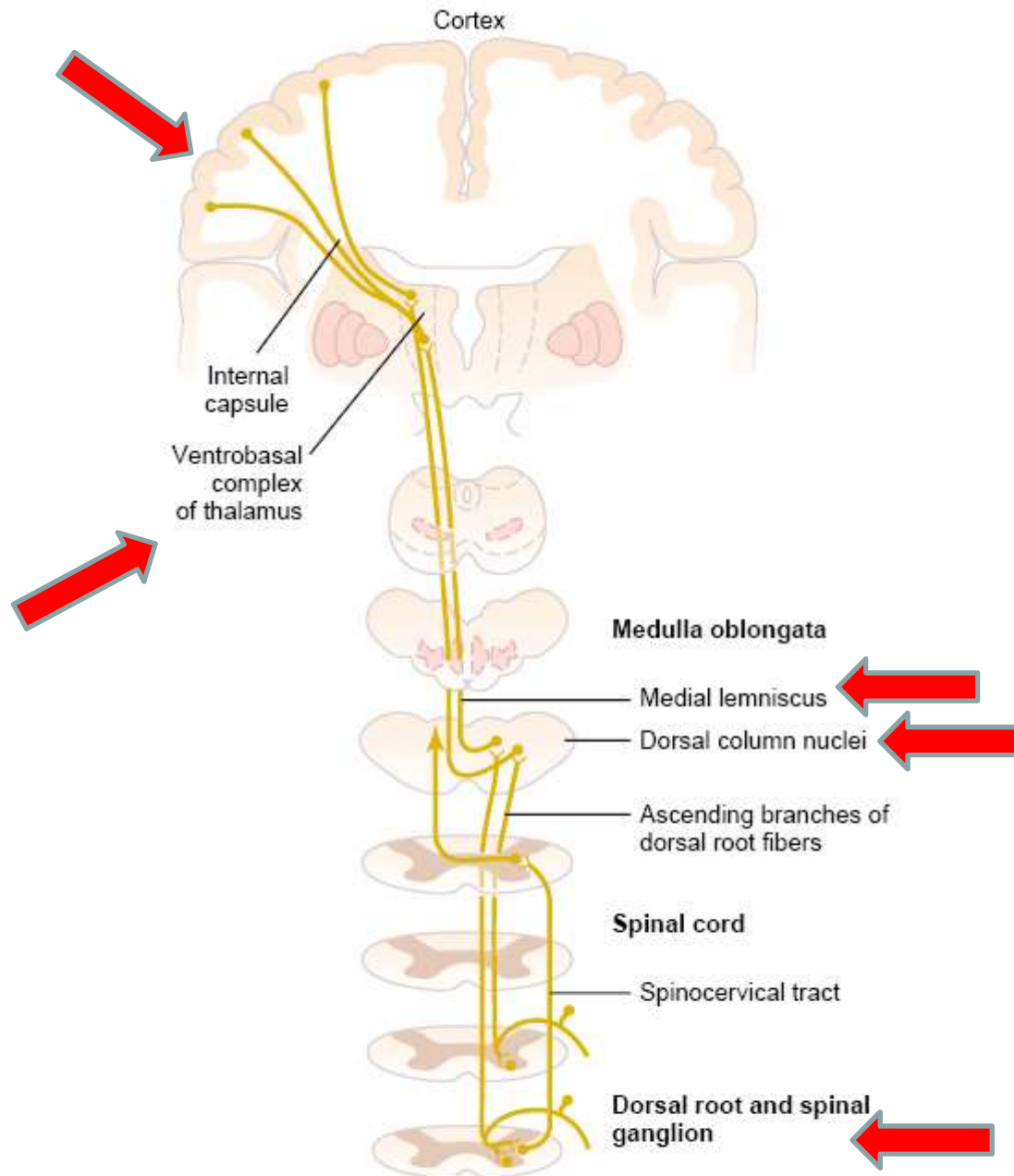


Figure 47-3

The dorsal column–medial lemniscal pathway for transmitting critical types of tactile signals. (Modified from Ranson SW, Clark SL: *Anatomy of the Nervous System*. Philadelphia: WB Saunders Co, 1959.)

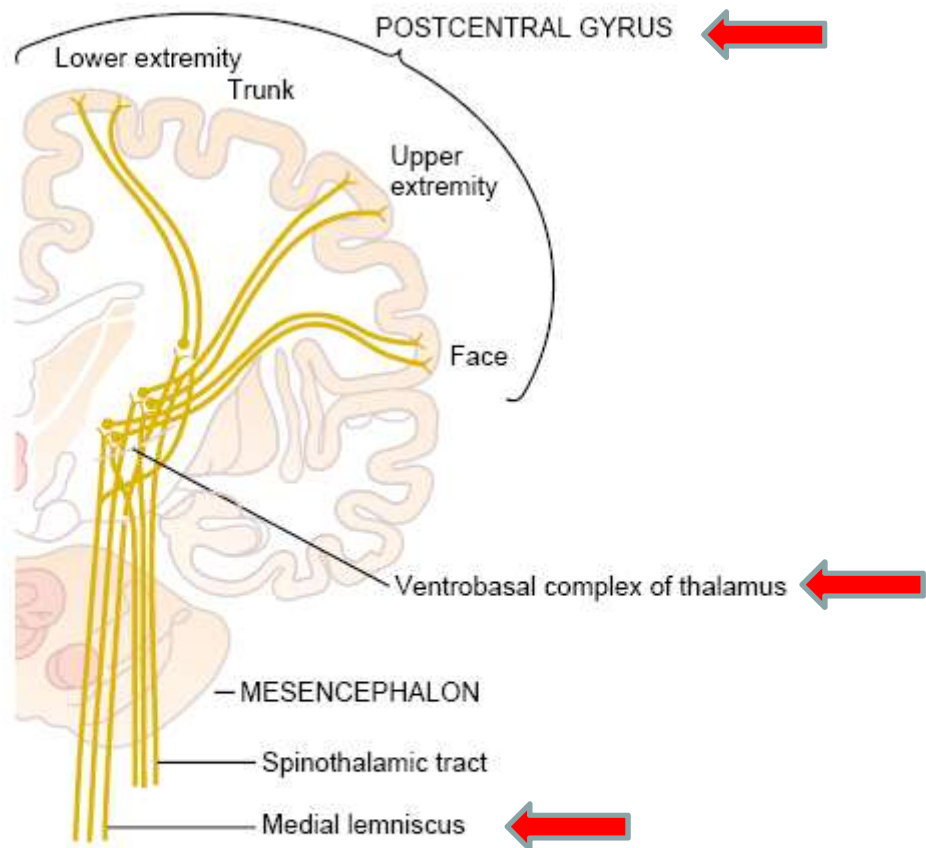


Figure 47-4

Projection of the dorsal column–medial lemniscal system through the thalamus to the somatosensory cortex. (Modified from Brodal A: *Neurological Anatomy in Relation to Clinical Medicine*. New York: Oxford University Press, 1969, by permission of Oxford University Press.)

(2) Anterolateral system Anterolateral = anterior + lateral

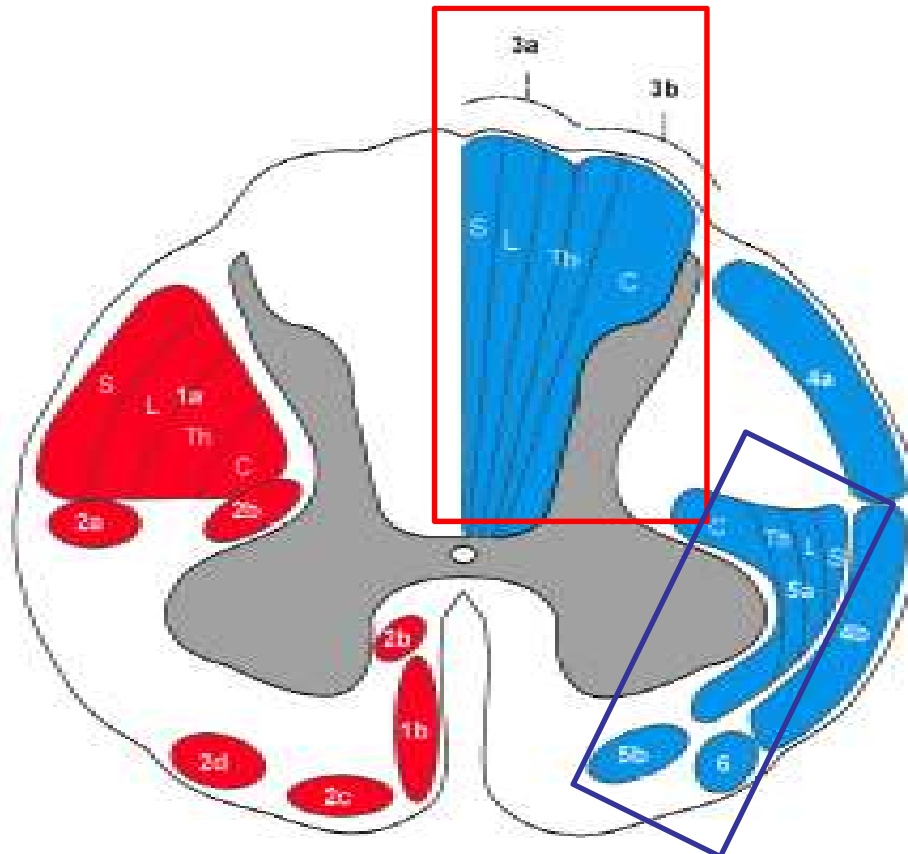
- First entering the spinal cord from the dorsal spinal roots
- Synapse in the dorsal horns of the spinal gray matter
- Cross to the opposite side of the cord
- Ascend through the anterior and lateral white columns
- Terminate at all levels of the brain stem and in the thalamus
- Smaller myelinated fibers. Transmit signals at velocities from a few meters per sec up to 40m/sec
- Smaller degree of spatial orientation
- No need to be transmitted rapidly or with great spatial fidelity
- A broad spectrum of sensory modalities: pain, warmth, cold, and crude tactile sensations

Types of sensations transmitted in the two systems

- (1) Dorsal column-medial lemniscal system: Touch, phasic sensations, position, pressure
- (2) Anterolateral system: pain, thermal sensations, crude touch, tickle, itch, sexual sensations

Anterolateral System

- Spinothalamic tract
- Spinoreticular tract
- Spinotectal tract



Motor and descending (efferent) pathways (left, red)

1. Pyramidal Tracts

- 1a. Lateral corticospinal tract
- 1b. Anterior corticospinal tract

2. Extrapyrmidal Tracts

- 2a. Rubrospinal tract
- 2b. Reticulospinal tract
- 2c. Vestibulospinal tract
- 2d. Olivospinal tract

Somatotopy Abbreviations:

S: Sacral, L: Lumbar
Th: Thoracic, C: Cervical

Sensory and ascending (afferent) pathways (right, blue)

3. Dorsal Column Medial Lemniscus System

- 3a. Gracile fasciculus
- 3b. Cuneate fasciculus

4. Spinocerebellar Tracts

- 4a. Posterior spinocerebellar tract
- 4b. Anterior spinocerebellar tract

5. Anterolateral System

- 5a. Lateral spinothalamic tract
- 5b. Anterior spinothalamic tract

6. Spino-olivary fibers

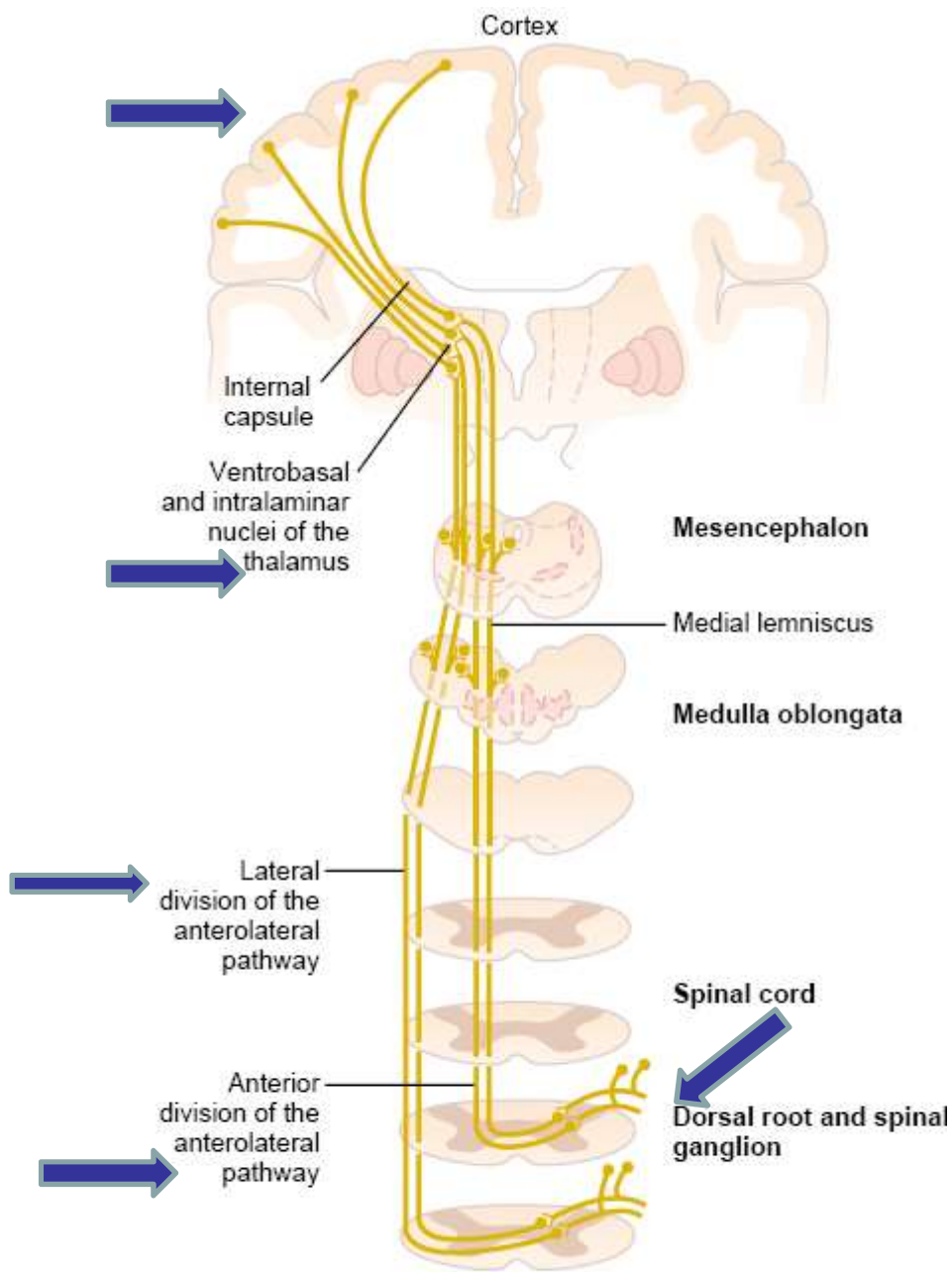
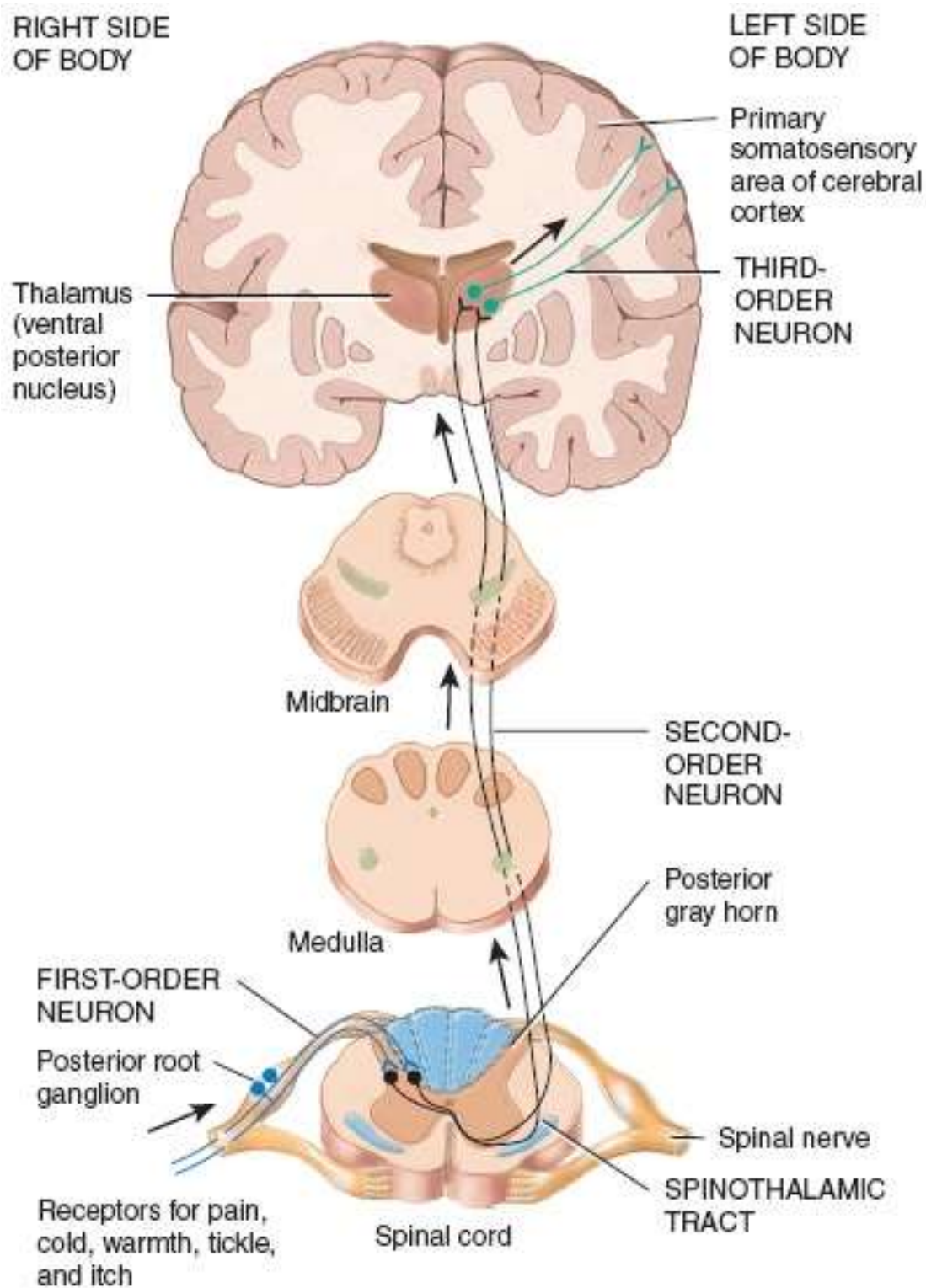


Figure 47-13

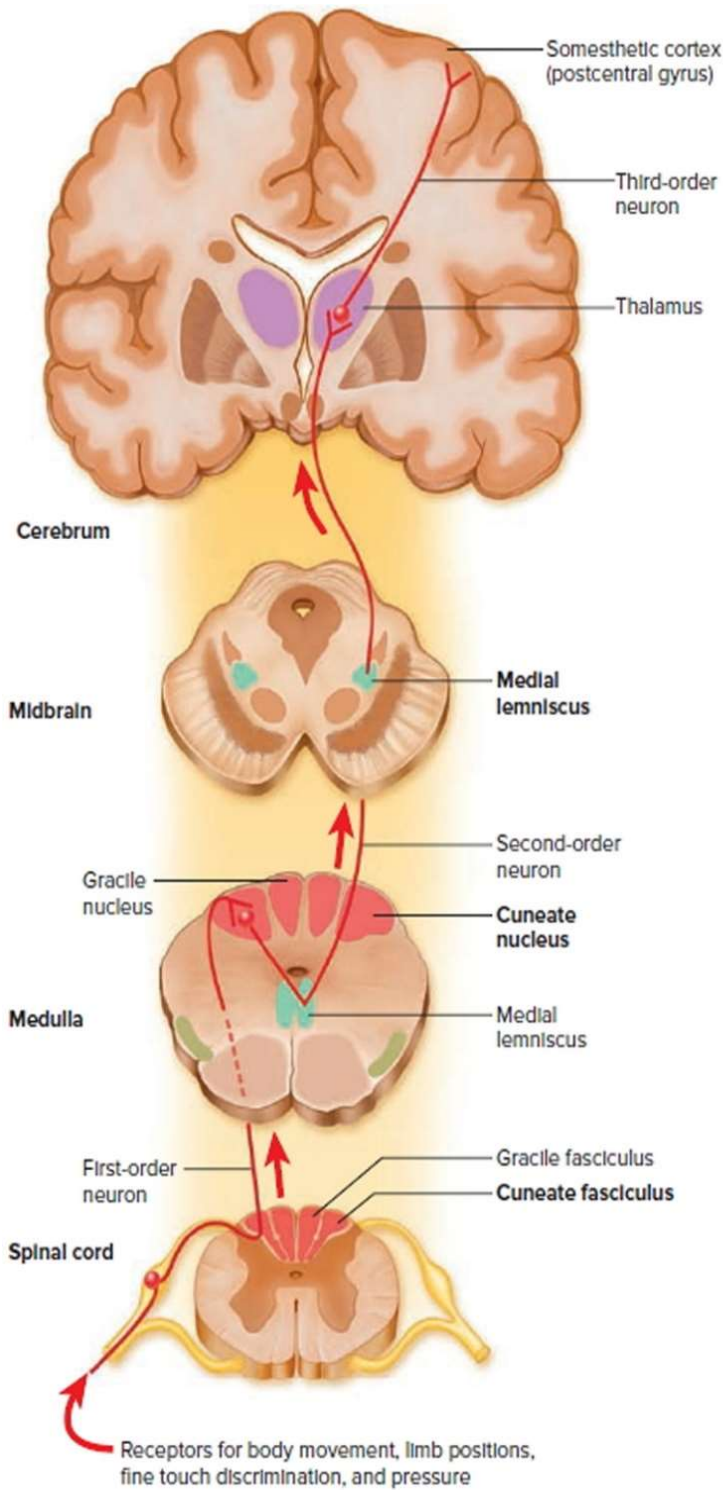
Anterior and lateral divisions of the anterolateral sensory pathway.

- Anterior spinothalamic track: crude touch and pressure
- Lateral spinothalamic track: pain and temperature

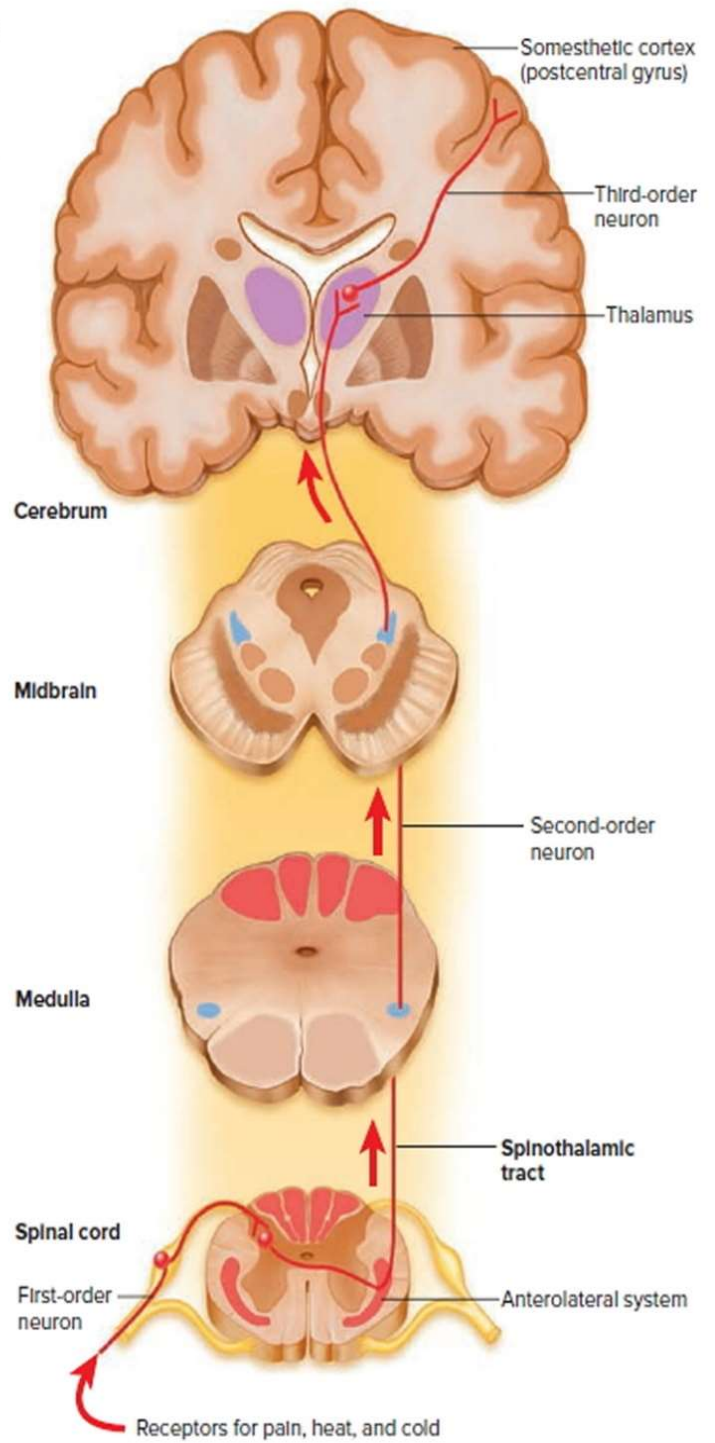


http://higheredbcs.wiley.com/legacy/college/tortora/0470565101/hearthis_ill/pap13e_ch16_illustr_audio_mp3_a/m/simulations/hear/anterolateral.html

Anterolateral System



Dorsal column-medial lemniscal system



Anterolateral System

- ◆ **Transmission in the dorsal column-medial lemniscal system**
- Anatomy of dorsal column-medial lemniscal system
 - Fig. 47-3
 - Spatial orientation of the nerve fibers in the dorsal column-medial lemniscal system is maintained: the fibers from the lower parts of the body lie toward the center of the cord, the fibers enter the cord at higher segmented levels form successive layers laterally
 - Crossing of the medial lemnisci in the medulla, the left side of the body is represented in the right side of the thalamus and the right side in the left side of the thalamus
- Somatosensory cortex
 - Fig. 47-5: Brodman's areas: 50 distinct areas
 - Somatosensory Areas I & II, Fig. 47-6
 - Fig. 47-7
 - Layers of the somatosensory cortex and their functions
 - Cerebral cortex contains six layers of neurons
 - Fig. 47-8
 - Incoming sensory signal excites neuronal layer IV first, signals spread both toward the surface of the cortex and toward the deeper layers
 - Layers I and II receive diffuse, nonspecific input signals from lower brain centers
 - Neurons in layers II and III send axons to related portions of the cortex
 - Neurons in layers V and VI send axons to the deeper parts of the nervous system.

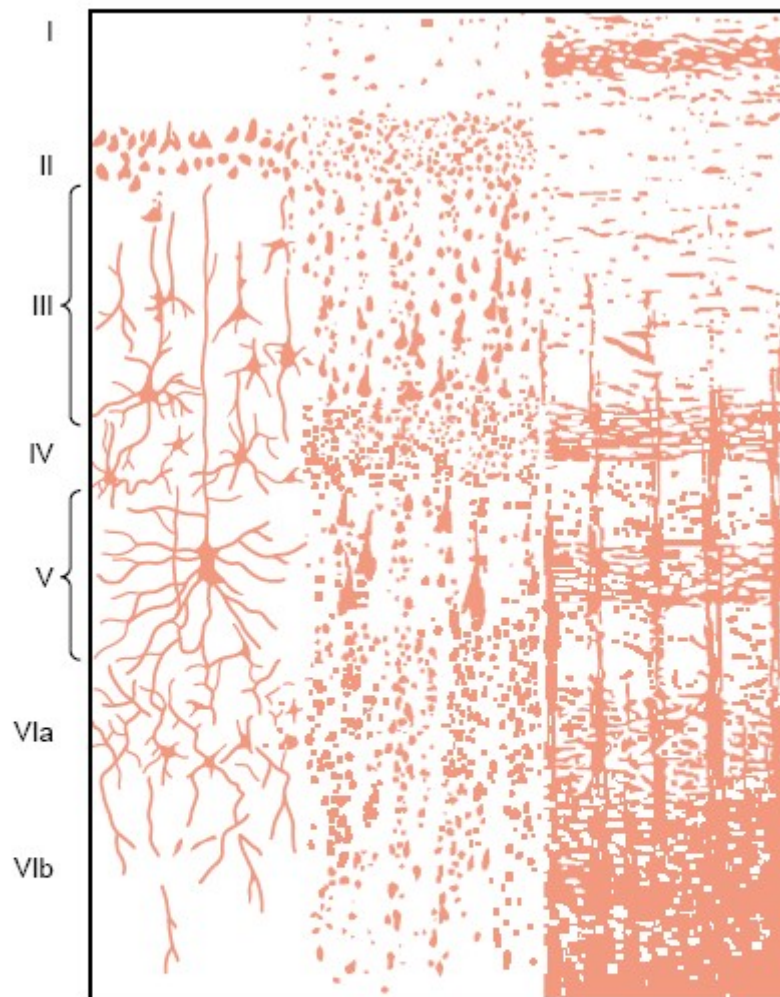
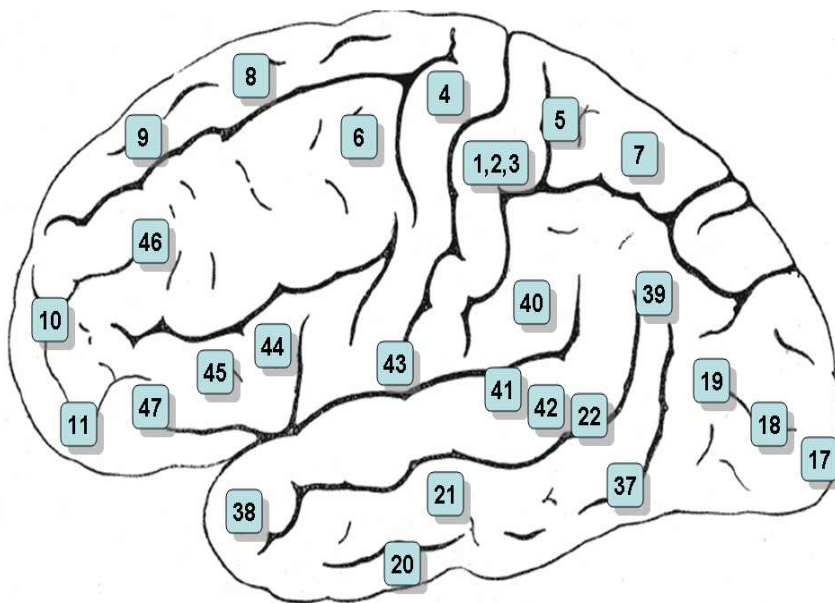


Figure 47-8

Structure of the cerebral cortex, showing I, molecular layer; II, external granular layer; III, layer of small pyramidal cells; IV, internal granular layer; V, large pyramidal cell layer; and VI, layer of fusiform or polymorphic cells. (From Ranson SW, Clark SL [after Brodmann]: *Anatomy of the Nervous System*. Philadelphia: WB Saunders, 1959.)

Korbinian Brodmann

- **Korbinian Brodmann**, a [German neurologist](#) who became famous for his definition of the [cerebral cortex](#) into 52 distinct regions from their [cytoarchitectonic](#) (histological) characteristics.



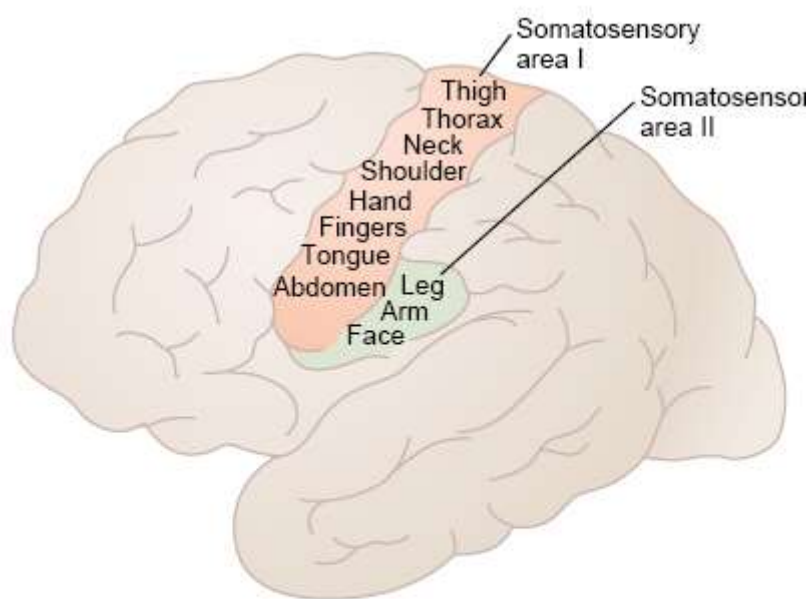


Figure 47-6

Two somatosensory cortical areas, somatosensory areas I and II.

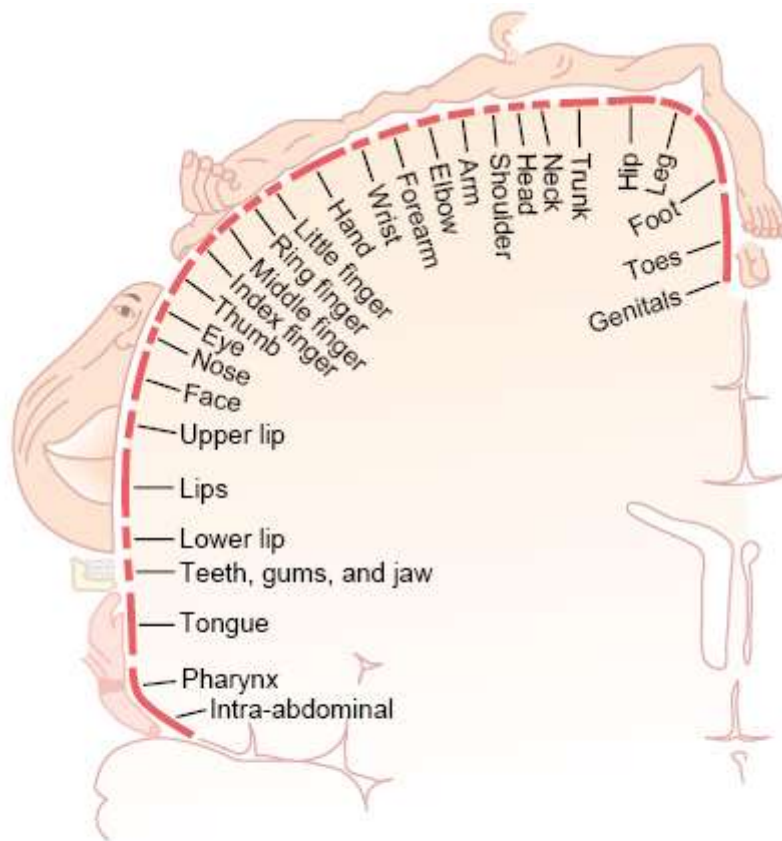


Figure 47-7

Representation of the different areas of the body in somatosensory area I of the cortex. (From Penfield W, Rasmussen T: Cerebral Cortex of Man: A Clinical Study of Localization of Function. New York: Hafner, 1968.)

- Sensory cortex contains vast numbers of vertical columns of neurons: Each column detects a different sensory spot on the body with a specific sensory modality
- Functions of somatosensory area I: in case of excision of somatosensory area I
 - Unable to localize the different sensations in different parts of the body
 - Unable to judge critical degrees of pressure
 - Unable to judge the weights of objects
 - Unable to judge texture of materials
- Regarding pain and temperature, in the absence of area I may not affect significantly affect their sensation, but they are poorly localized. The area I involved for localization of their source
- Somatosensory association areas
 - Brodman's area 5 and 7
 - Important roles in deciphering the sensory information
 - Combines information arriving from multiple points in the primary somatosensory area to decipher its meaning
 - Effect of removing the somatosensory association area: amorphosynthesis
- Overall characteristics of signal transmission and analysis in the dorsal-column-medial lemniscal system
 - Basic neuronal circuit in Fig. 47-9
 - Two-point discrimination
 - Effect of lateral inhibition in increasing the degree of contrast in the perceived spatial pattern: Fig. 47-10

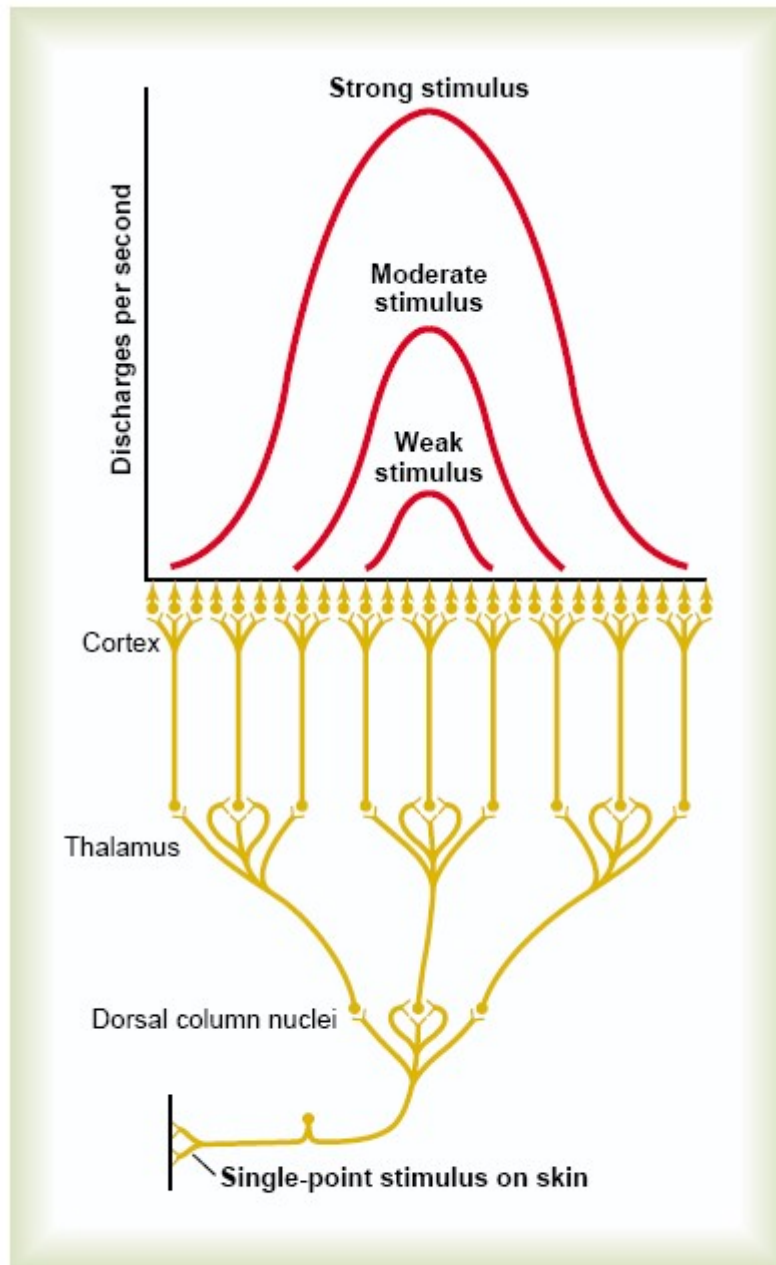


Figure 47-9

Transmission of a pinpoint stimulus signal to the cerebral cortex.

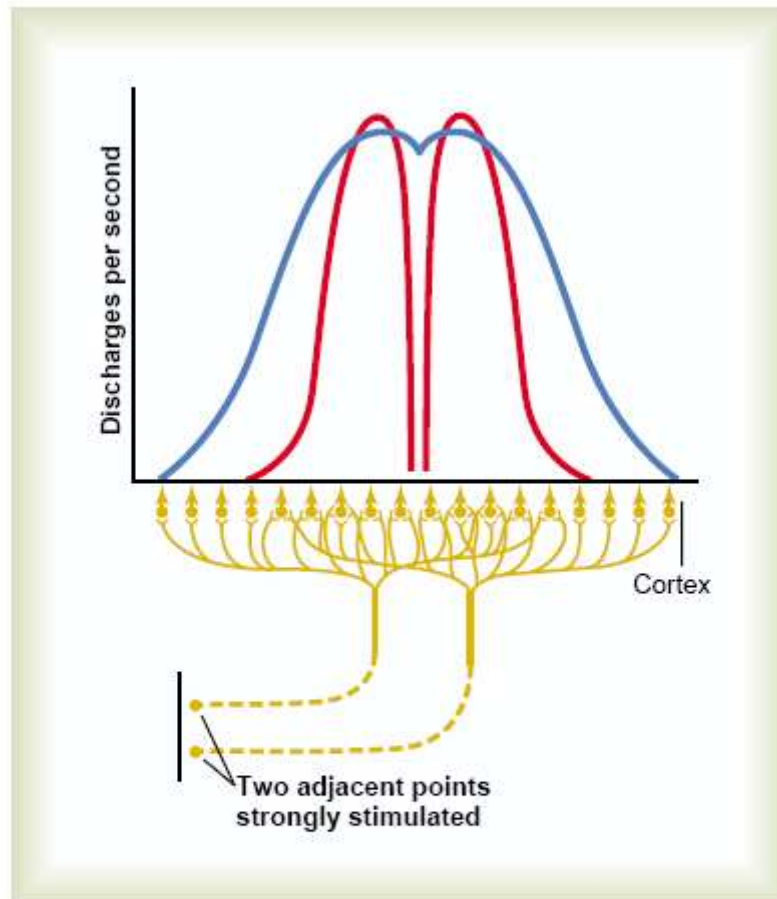


Figure 47-10

Transmission of signals to the cortex from two adjacent pinpoint stimuli. The blue curve represents the pattern of cortical stimulation without "surround" inhibition, and the two red curves represent the pattern when "surround" inhibition does occur.

- Position senses
 - Proprioceptive senses
 - Two subtypes (1) static position sense (2) rate of movement sense or dynamic proprioception
 - Position sensory receptors: skin tactile receptors and deep receptors near the joints
 - Muscle spindle: determine joint angulation

- ◆ **Transmission of less critical sensory signals in the anterolateral pathway**
 - Transmits signals that do not require highly discrete localization of the signal source and do not require discrimination of fine gradations of intensity
- Anatomy of the anterolateral pathway: Fig. 47-13
- Characteristics of transmission in the anterolateral pathway
 - Velocities of transmission are only $1/3$ to $1/2$ those of dorsal column-medial pathway
 - Degree of spatial localization of signals is poor
 - Gradations of intensities are far less accurate
 - Ability to transmit rapidly changing or rapidly repetitive signals is poor
 - A cruder type of transmission system than the dorsal column-medical system

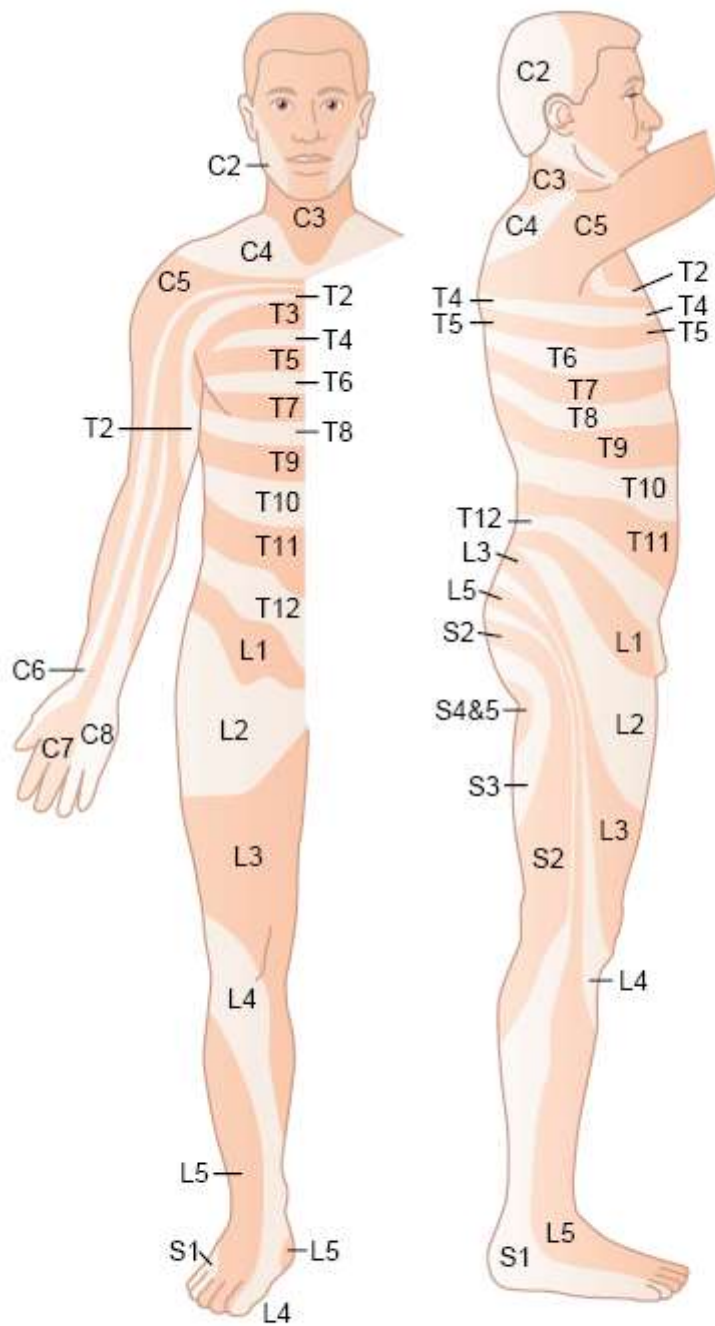
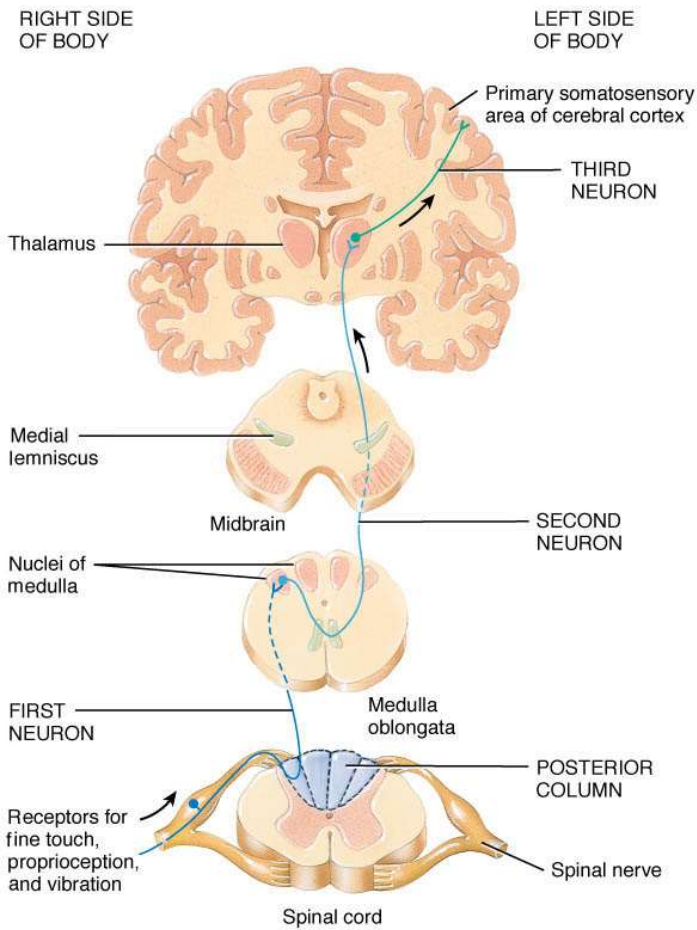


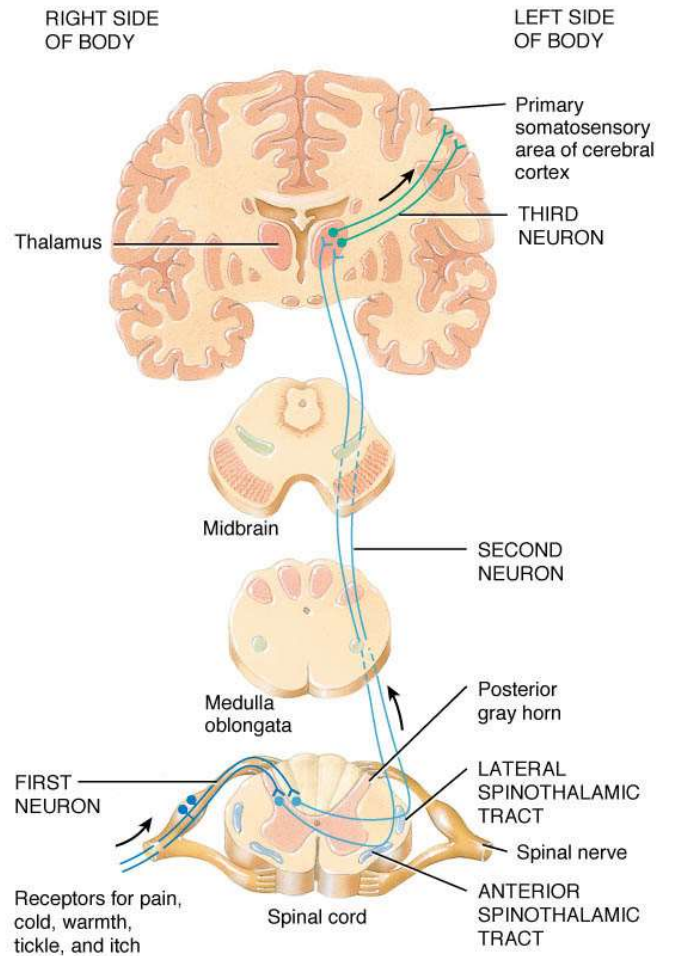
Figure 47-14

Dermatomes. (Modified from Grinker RR, Sahs AL: Neurology, 6th ed. Springfield, IL: Charles C Thomas, 1966. Courtesy of Charles C Thomas, Publisher, Ltd., Springfield, Illinois.)

Quiz



(a) Posterior column–medial lemniscus pathway



(b) Anterolateral (spinothalamic) pathways

Which one is the Dorsal column-medial lemniscal system or Anterolateral system???